

Dr. Jose Luis Antonaya

Follow-up case
Complutense de Madrid University.



Patient Description

Gender and age of the patient:

- Male gender, age 56 years.

Case follow-up:

14/10/2019 - First Visit.

Treatment plan:

1. Upper Full Arch restoration, four implants, position 1.3, 1.5, 2.3, 2.5, with multiunit abutment.
2. Mandibular Full arch restoration, six implants, position 3.1, 3.3, 4.1, 4.3, 3.6, 4.6

Treatment Sequence:

4/11/2019- Intraoral Scan impressions.

20/11/2019- Aesthetic test.

4/12/2019- Placement of the upper and mandibular Graphene structure.

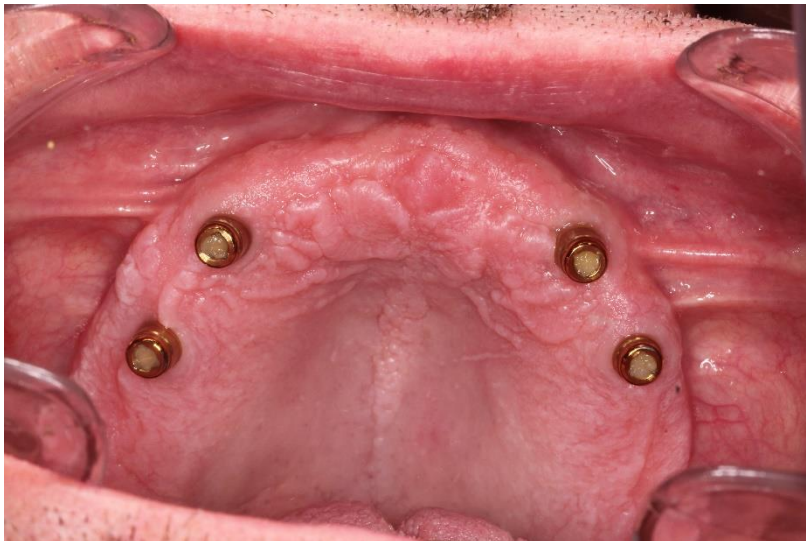
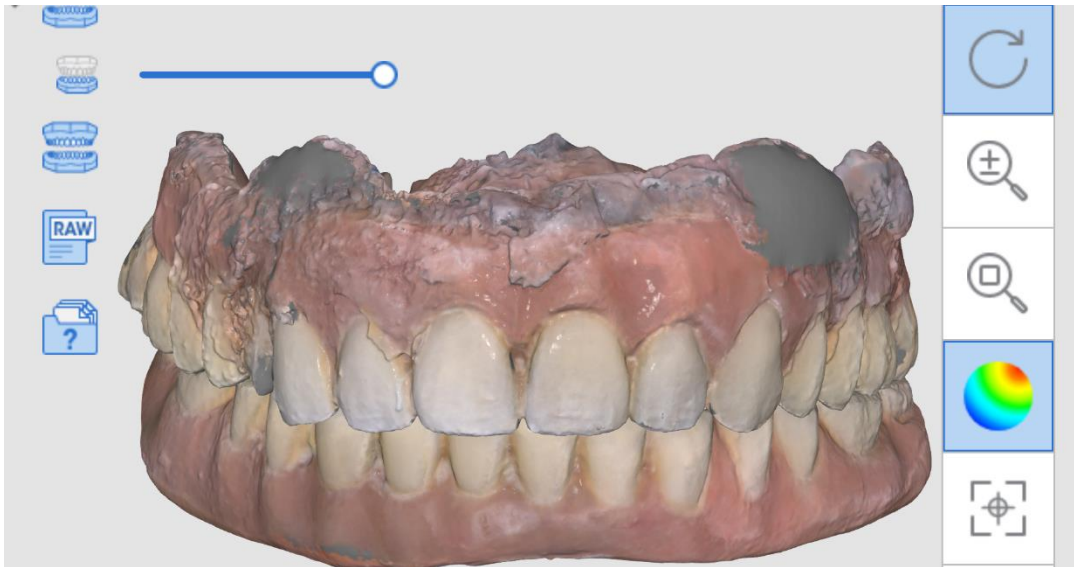
11/12/2019- Review and occlusal adjustment.

23/7/2020- First review and occlusal adjustment.

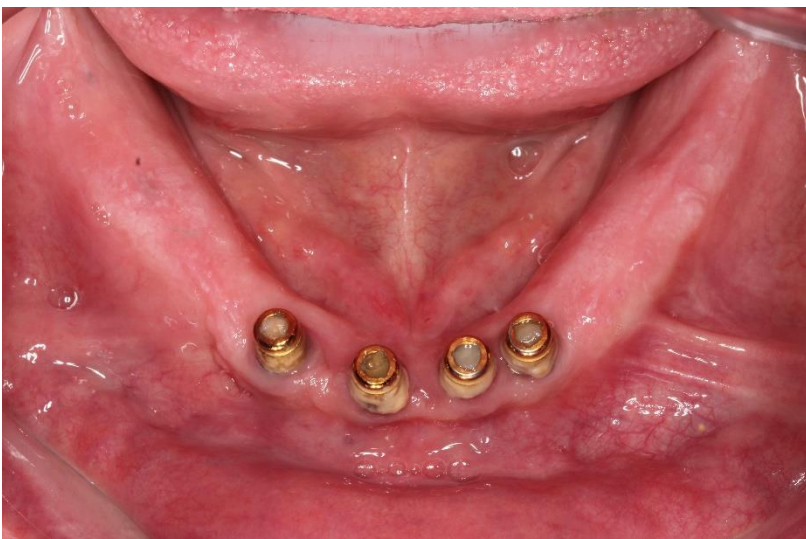10/3/2021- Second review. Remove prosthesis to carry out maintenance cleaning revision.

Treatment plan

Before Denture



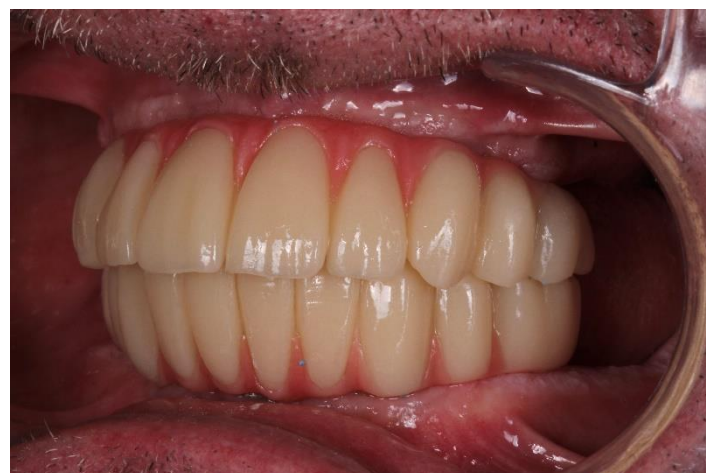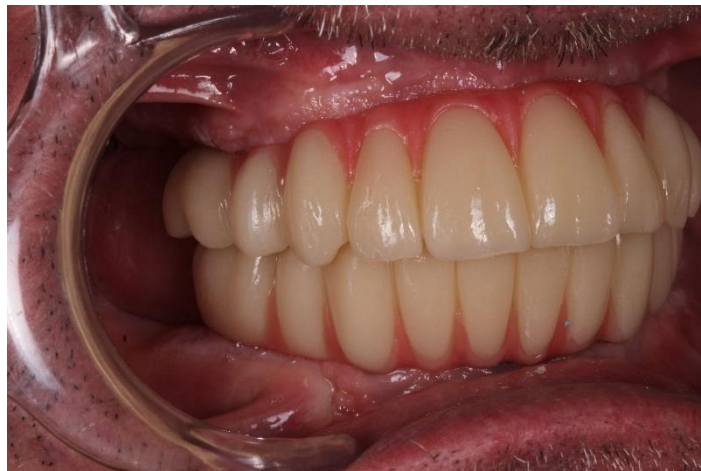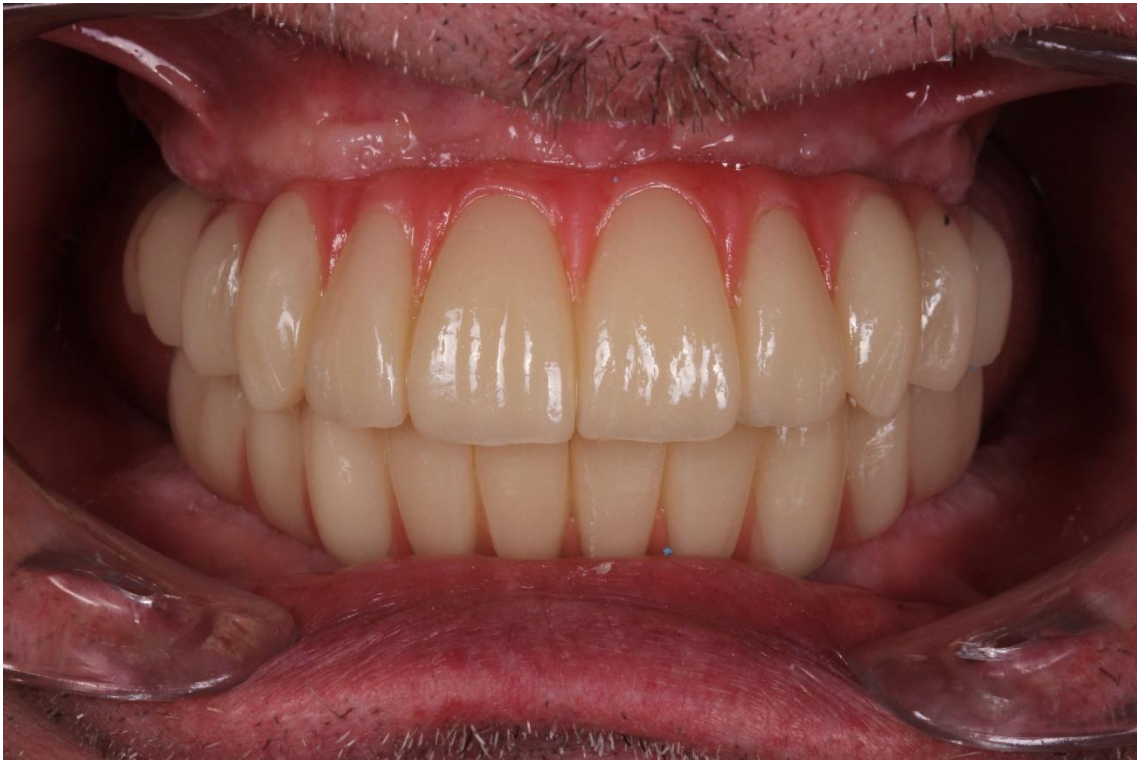Upper Arch



Mandibular Arch

Definitive Prosthesis

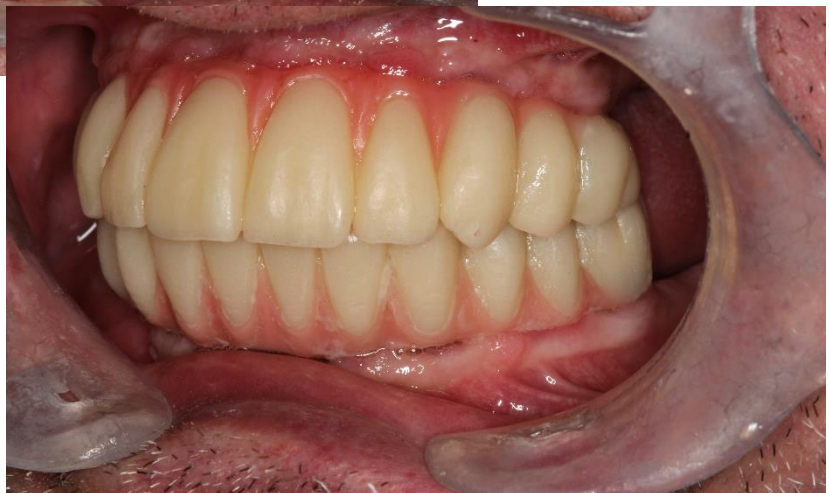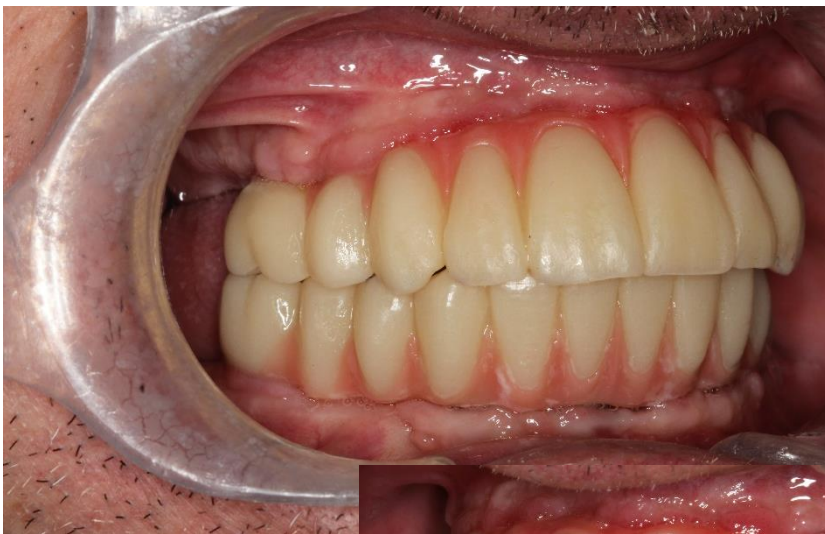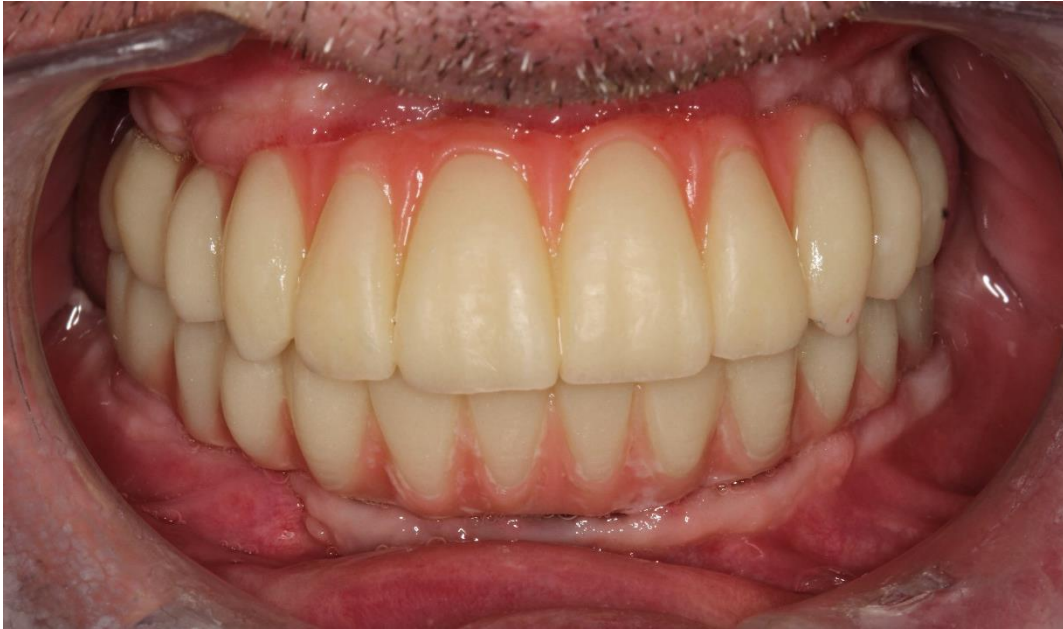Placement date 4/12/2019



Definitive Prosthesis

Dental review 23/07/2019

Prosthesis review: occlusal check correct, good colour stability and not bacterial plaque.



Definitive Prosthesis Dental review 10/03/2021

Prosthesis review: occlusal check correct, the colour is stable, not bacterial plaque and good hygiene. Prosthesis correct.

