

## **Dr. Jose Luis Antonaya**

Follow-up case  
Complutense de Madrid University.



### **Patient Description**

#### **Gender and age of the patient:**

- Male gender, age 58 years.

#### **Case follow-up:**

4/2/2021 - First Visit.

#### **Treatment plan:**

1. Graphene Complete removable prosthesis.
2. Tooth extraction 3.3, 3.4, 3.7, 4.3
3. Mandibular full arch prosthesis, five implants Biotech Kontakt with conical abutments, platform 4,9, positions 3.4, 3.6, 4.1, 4.4, 4.6. Immediate load.

#### **Treatment Sequence:**

23/3/2021- Tooth extraction and placement of the implants (ISQ 3.6=69, 3.4=70, 4.1=69, 4.4=70, 4.6=72). Impression registration.

24/3/2021- Placement of the provisional prosthesis.

5/5/2021- Review of the provisional prosthesis.

9/6/2021- New impressions registration, to perform the definitive prosthesis with Graphene.

16/6/2021. Aesthetic upper and mandibular Graphene test. Aesthetic modifications.

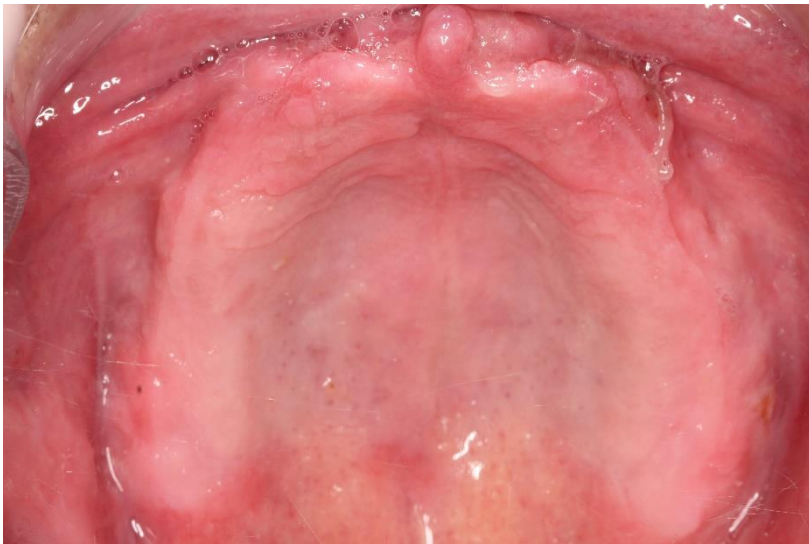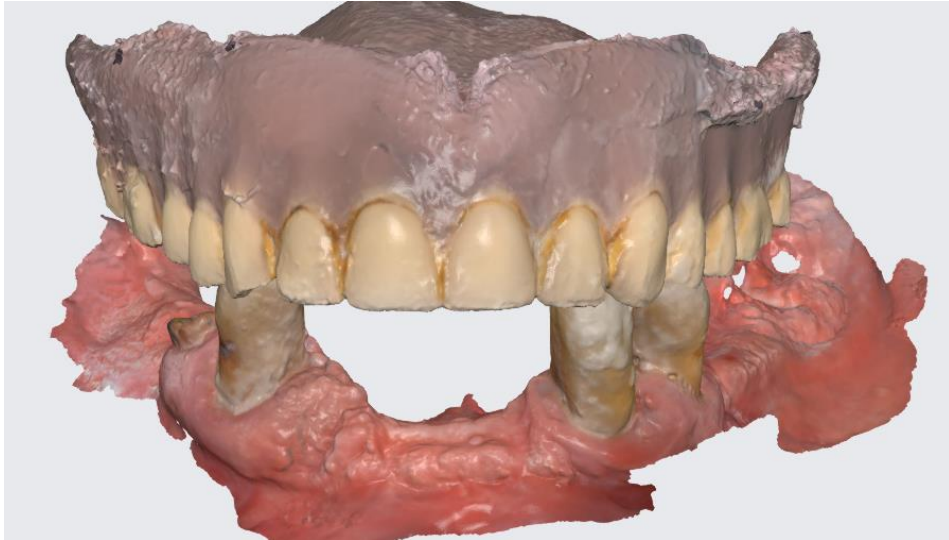
14/7/2021- New aesthetic Graphene test.

20/9/2021- Placement of the definitive Graphene prosthesis.

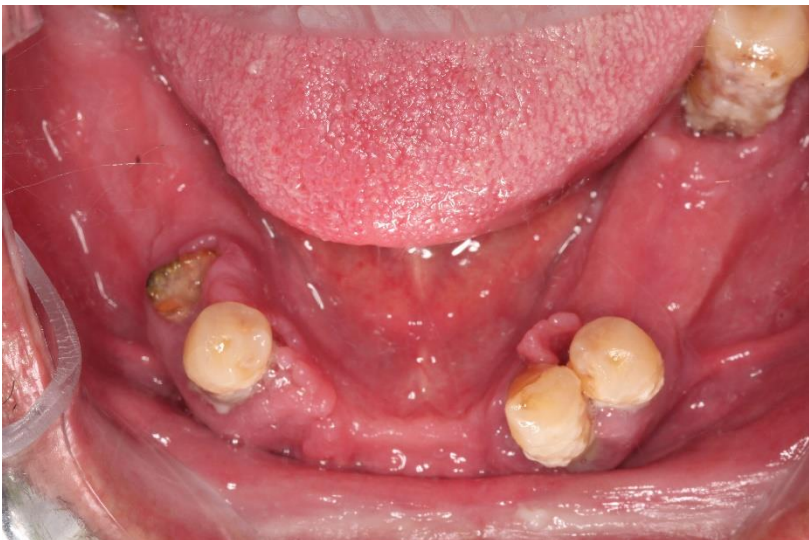22/10/2021- Review and occlusal adjustment. Prosthesis review occlusal check, colour stability and hygienic prosthesis.

## Treatment plan

### Before Denture



**Upper Arch**



**Mandibular Arch**

**Definitive Prosthesis**

**Placement date 20/09/2021**

