

PRESCRIPTOR	VICTOR HENAREJOS DOMINGO
PACIENTE (NHC)	<div></div>
LABORATORIO	GRAPHENANO DENTAL
ADJUNTO	FOTOGRAFÍAS + PDF

FECHA ENTREGA	15/02/21
---------------	----------

BLASI

Clínica Dental

Barcelona



DOCUMENTACIÓN

NO DOCUMENTACIÓN

Tipo de medidas	<input type="checkbox"/> Convencionales
	<input checked="" type="checkbox"/> Digitales

MARCA IMPLANTES	BIOHORIZONS
DIAMETRO	<p>Implante en 1.4 = 4.6 x 10.5 mm Tissue level (Plataforma 4.5 mm - verde)</p> <p>Implante en 2.4 = 4.2 x 12 mm Bone Level. (Plataforma 3.5 mm - amarilla)</p>
CONEXIÓN	<p>1.4= Plataforma 4.5 (verde)</p> <p>2.4= Plataforma 3.5 (amarilla)</p>
ADITAMENTOS	<p>1.4= ANÁLOGO DE 4.5 + INTERFASE</p> <p>2.4= ANÁLOGO DE 3.5 + INTERFASE</p>
SCAN BODY	<p>1.4= SCAN BODY DE BIOHORIZONS DE 4.5</p> <p>2.4= SCAN BODY DE BIOHORIZONS DE 3.5</p>
MODELO A IMPRIMIR	SÍ

FECHA ENTREGA

**15/02/21**

**BLASI**

Clínica Dental

Barcelona



# Indications

Delivery **15/02/21**

1. **Final Prosthesis to be performed:** Screw-cement Implant prosthesis 1.4 and 2.4
2. **Material:** Graphenano Dental (G-CAM)
3. **Comments:** Final colour A3. Characterization of periodontics teeth and fine occlusal stain.

## Patient Description

### **Gender and age of the patient:**

- Male gender, age 78 years (08/27/1942)

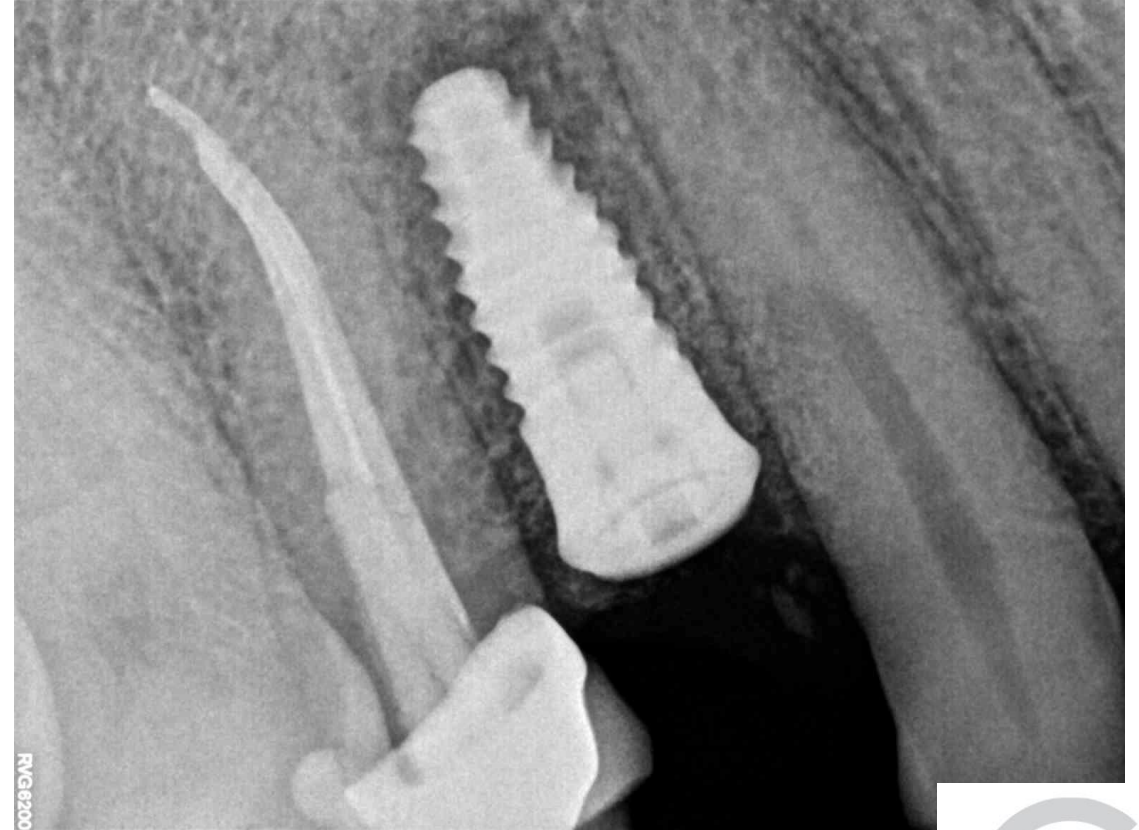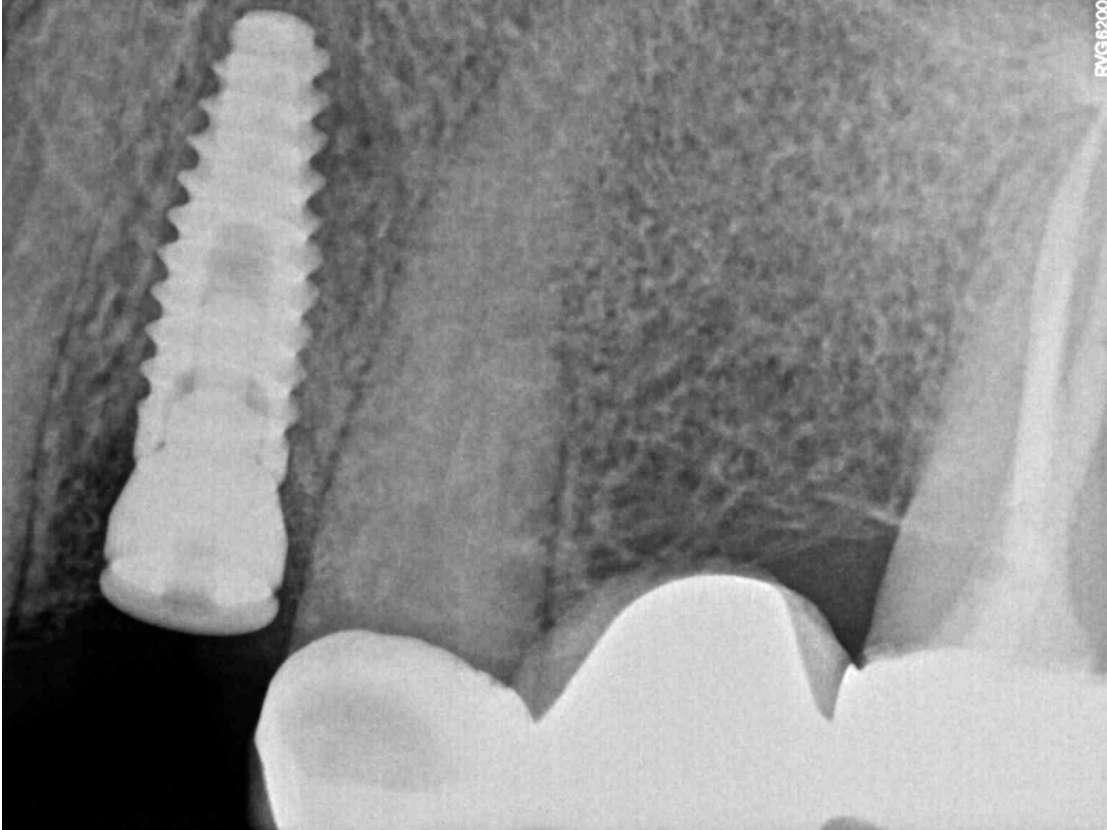### **Anamnesis: History, allergies, habits** (tobacco or parafunction), systemic pathologies and medication that you take.

- Allergies: Not known.
- Systemic pathologies: Respiratory asthma
- Current medication: Ventolin 100 micrograms / rescue inhalation
- Surgical history: Does not refer
- Toxic habits: No tobacco, no alcohol, no other drugs

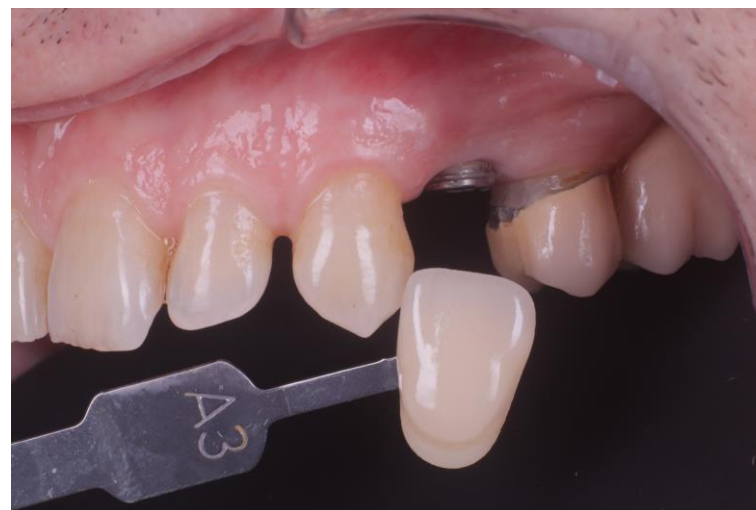
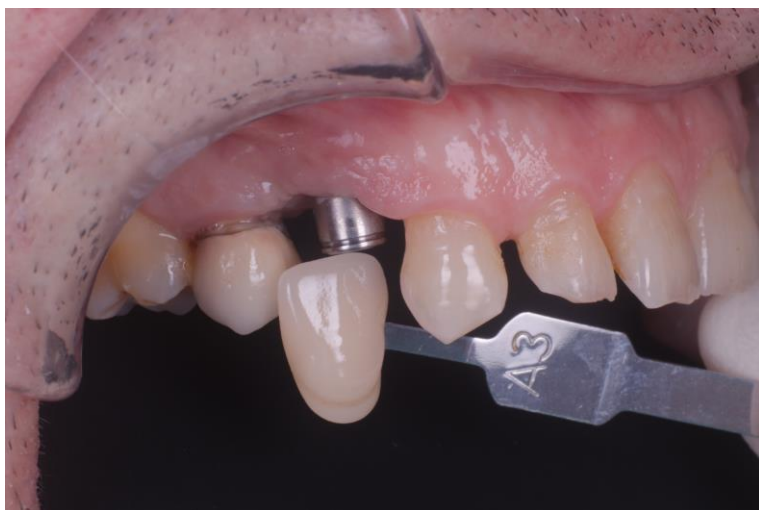
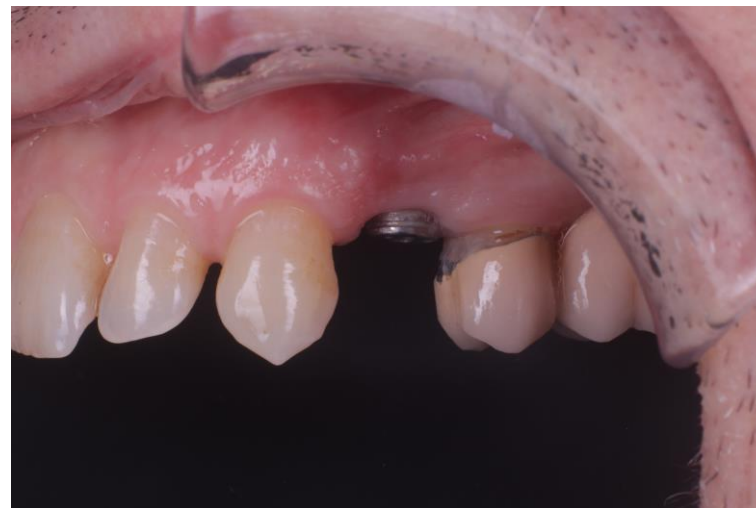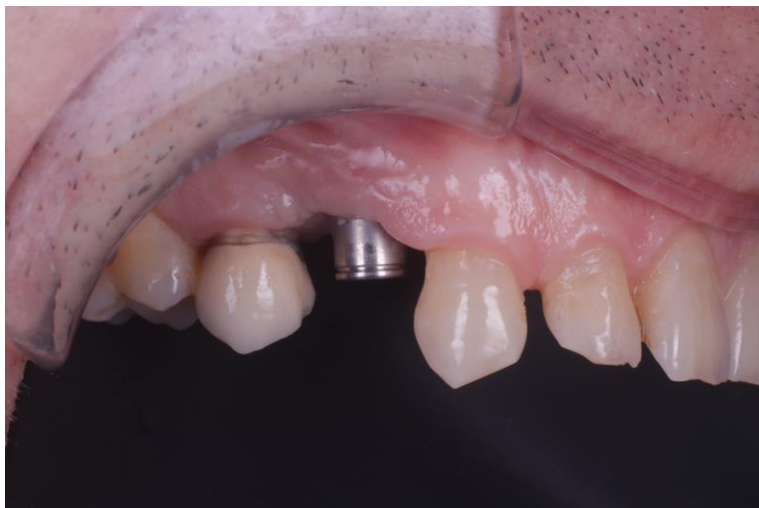# X-rays after implant placement.

Placement date 27/07/2020


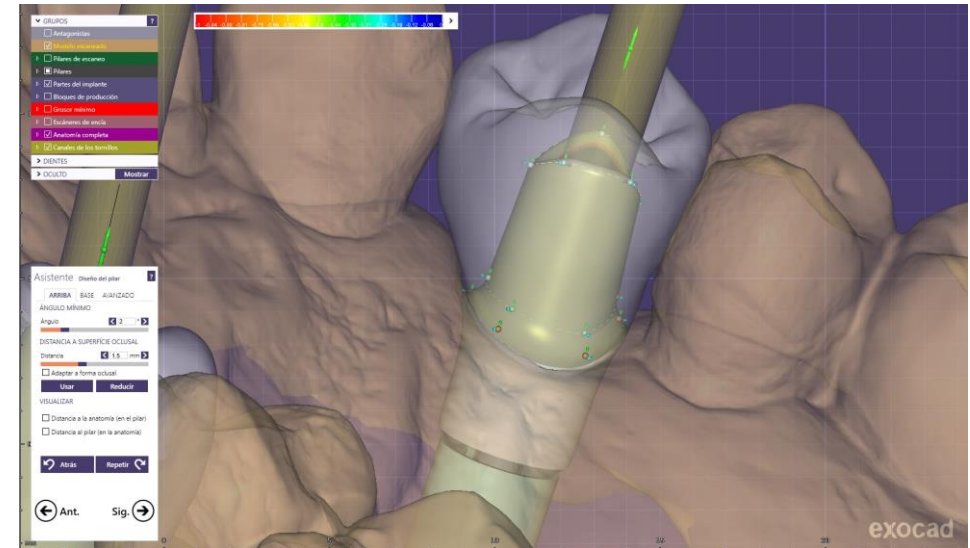
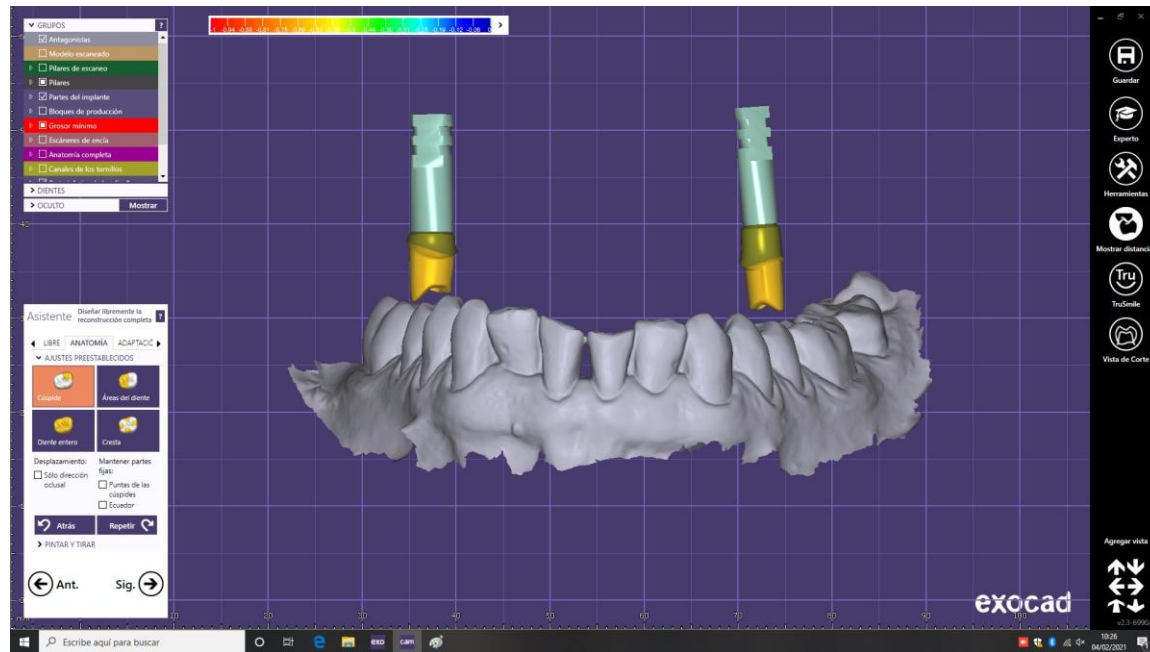


# Photography guide to make the prosthesis

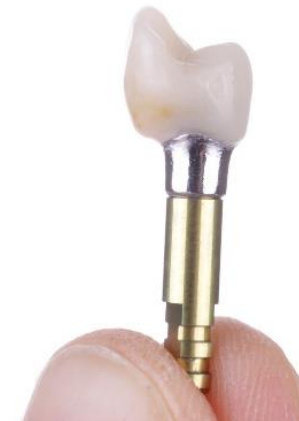
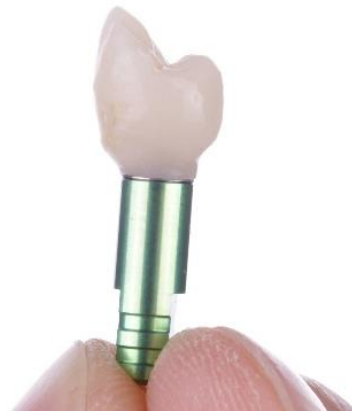
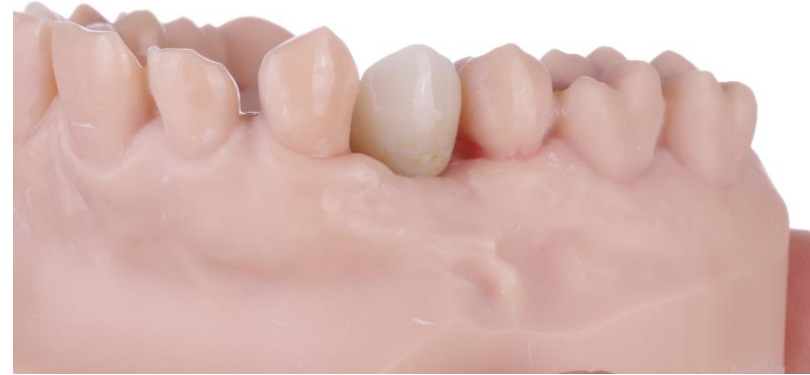
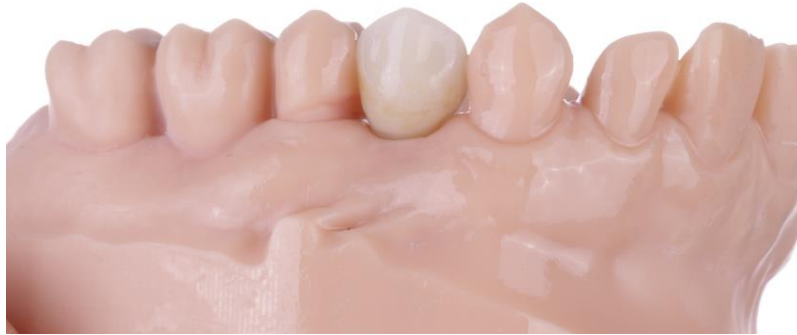
# Digital prosthesis design

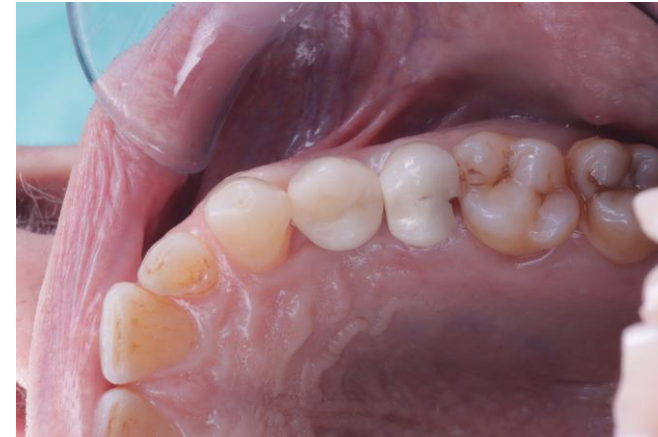
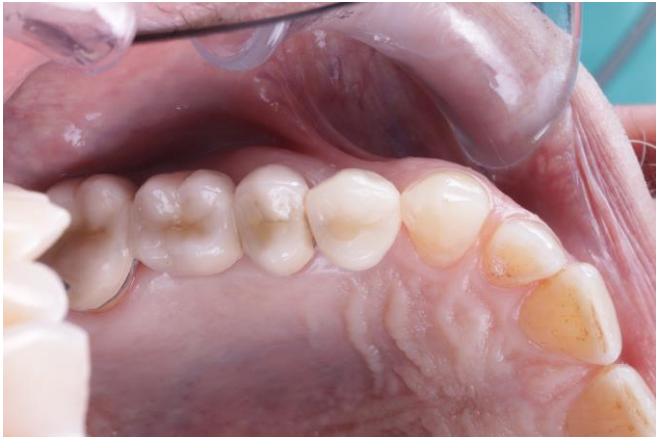
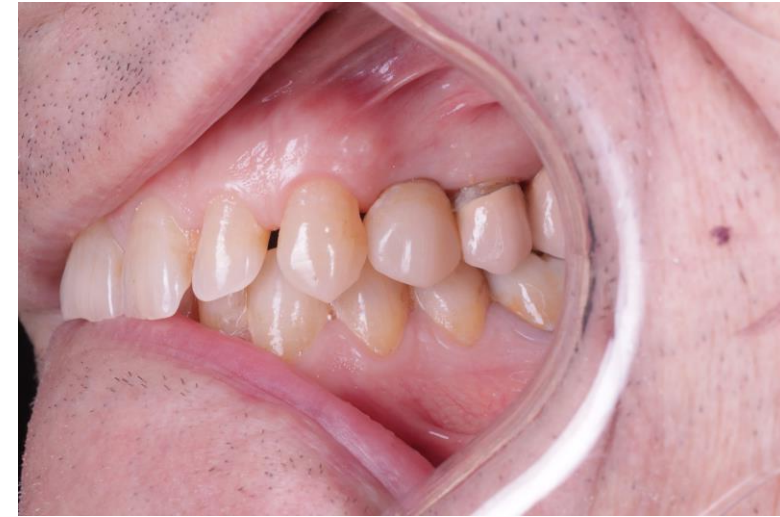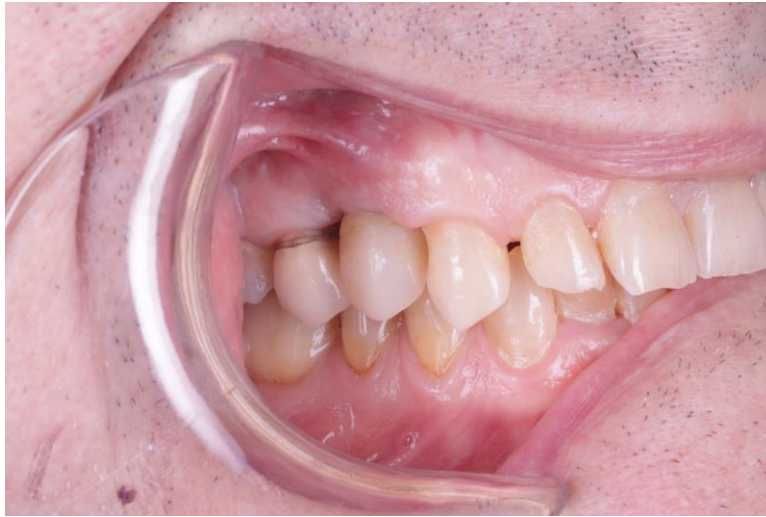# Finish Prosthesis



# Definitive Prosthesis

Placement date 23/03/2021



We check the occlusion and the color.

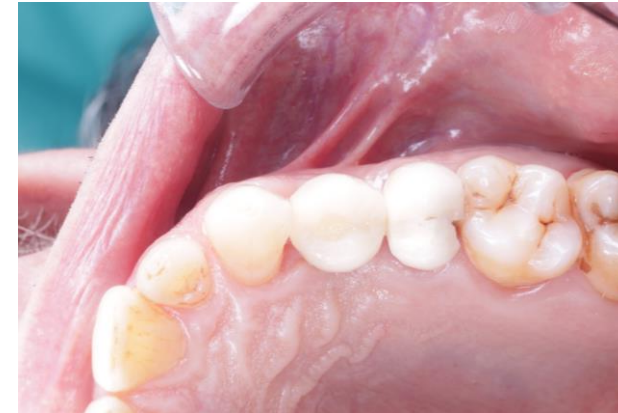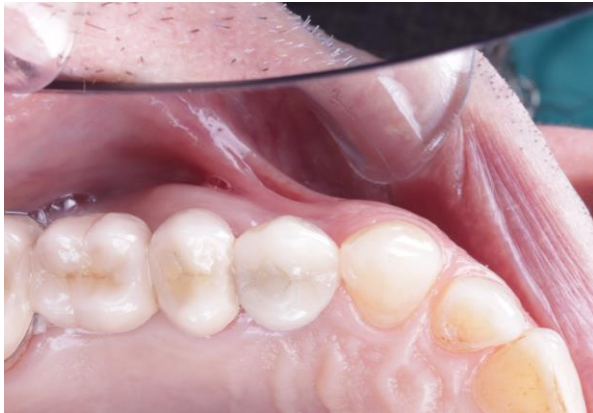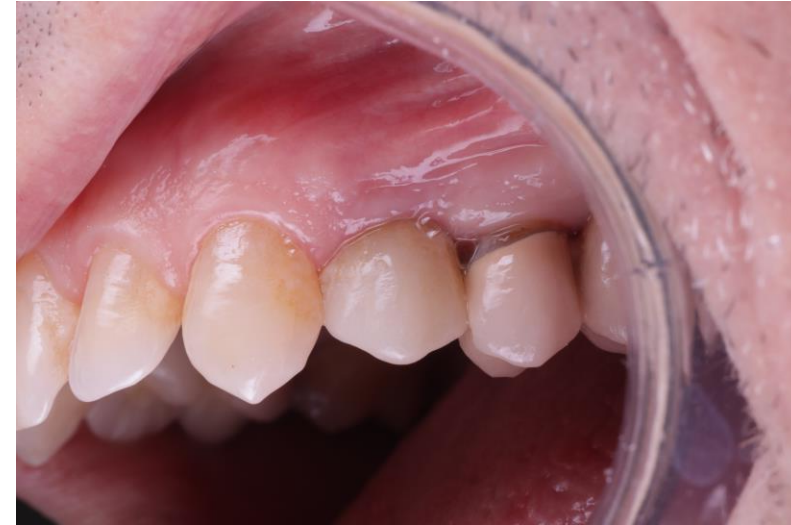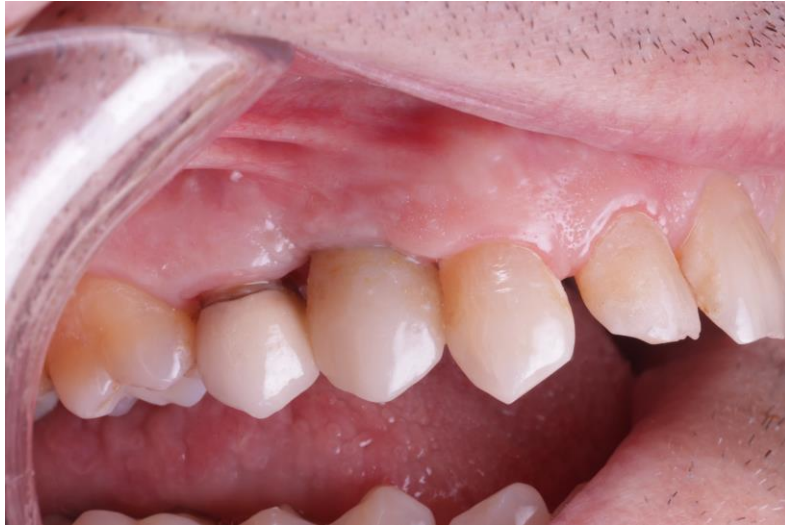The two implants crown are correct according to the specifications requested from the laboratory.





# Definitive Prosthesis

Dental review day 20/10/2021



First review: check the occlusion, color and dental hygiene.

After these months, we observed that the two implants crowns remained stable in occlusion, not observed bacterial plaque or occlusal wear.

